

Featured Patient Alert

00150100

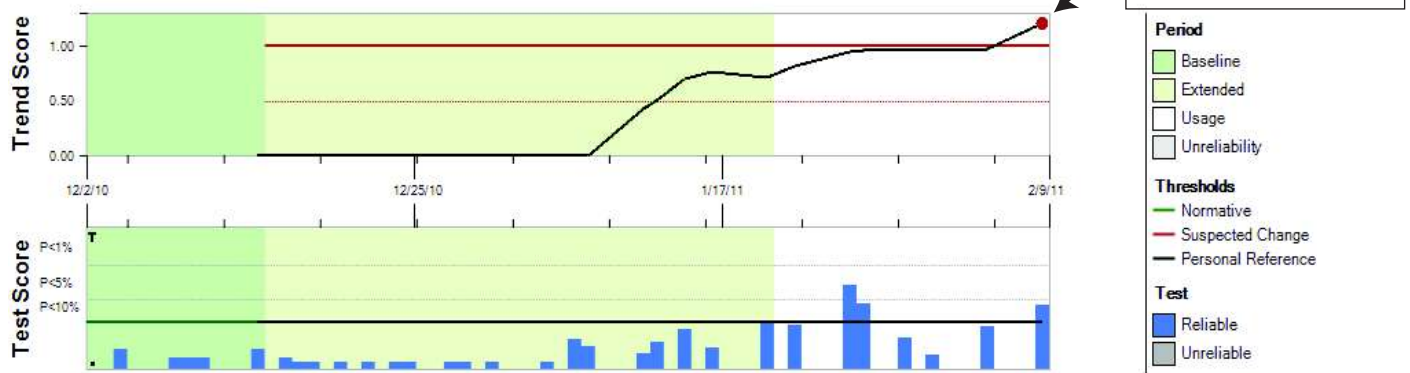
Patient History:

- 75 year old female
- OD at baseline (Dec. 2010):
 - VA 20/30
 - Dry AMD

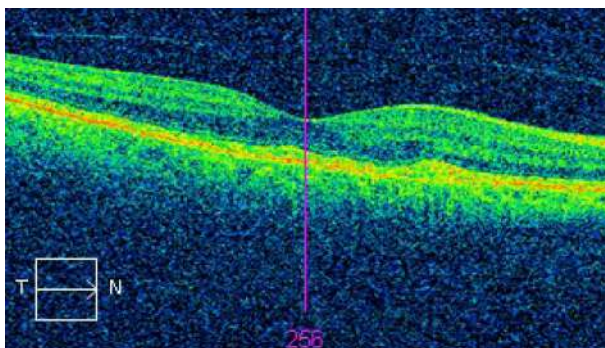
Testing:

- ForeseeHome testing began Dec, 12, 2011
- Average frequency of use ≈ 5 times/week

February 9, 2011: ForeseeHome Alert

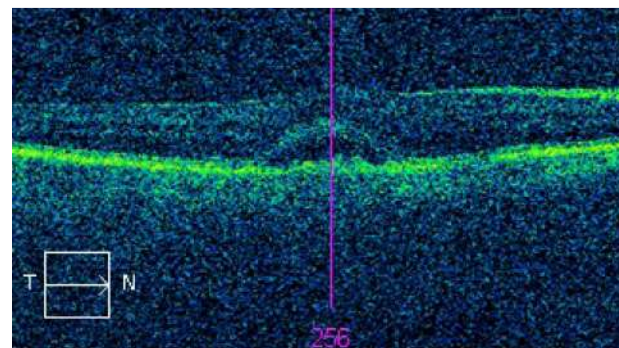


OCT Before Alert



December 30, 2010

OCT After Alert



February 14, 2011

A Word From the Doctor



After using the ForeseeHome AMD Monitor regularly for about a month and a half, my patient received a call from the Notal Vision Data Monitoring Center alerting her that they had detected a change in her test results. We immediately scheduled the patient to come in for an exam. An OCT and FA confirmed that she had indeed converted to wet AMD. At the time of the alert, the patient had noticed minimal visual change and had not identified any significant change on her amsler grid testing. Additionally, her visual acuity had not changed (20/30). With the help of the ForeseeHome, I was able to treat the lesion at the earliest possible stage and preserve my patient's good vision.

Gregory Fox, M.D.
Retina Associates
Shawnee, KS