

Featured Patient Alert

US21019

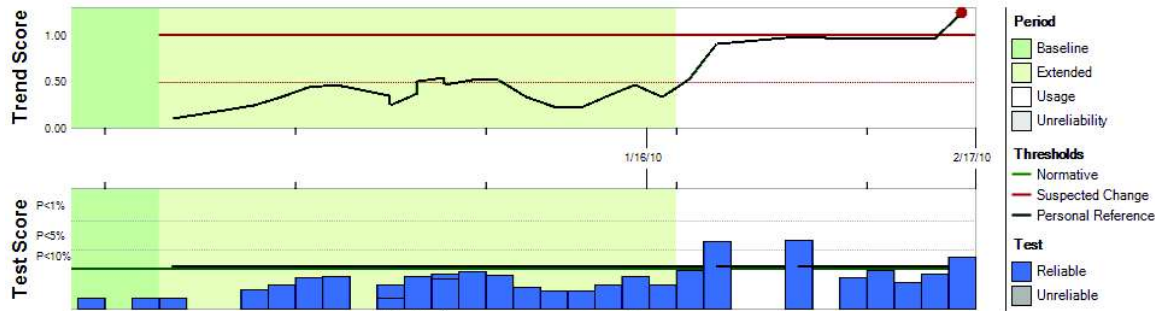
Patient History:

- 71 year old male
- Both eyes AMD at baseline (Nov. 2009)
 - OD: VA 20/60 - Treated CNV with Lucentis injections
 - OS: VA 20/20 (-2) - Drusenoid PED, Intermediate AMD

Testing:

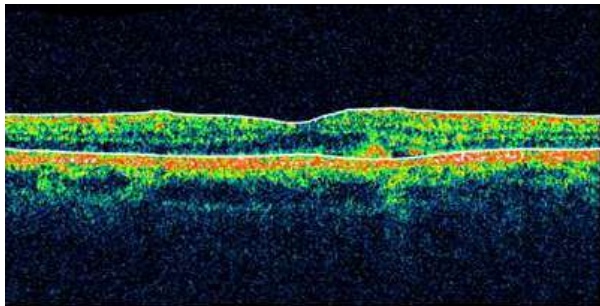
- ForeseeHome testing began Nov. 11, 2009
- Average frequency of use \approx 5.5 times/week

Feb. 17, 2010: ForeseeHome Alert



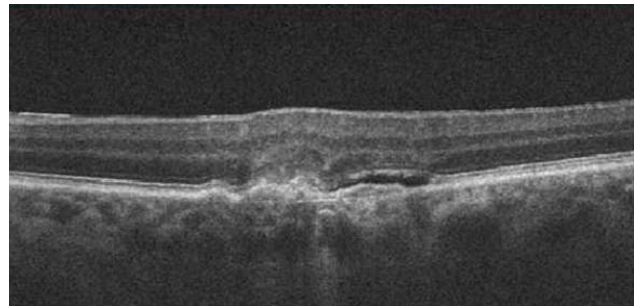
ALERT
VA 20/20
Patient experiencing no visual symptoms

Stratus OCT



March 8, 2010

Cirrus OCT



March 24, 2010

A Word From the Doctor



After my patient had been using the ForeseeHome AMD Monitor daily for about 3 months, I received an alert call from the Notal Vision Data Monitoring Center. We immediately scheduled the patient to come in to the office, and OCT and FA imaging confirmed conversion to wet AMD. At the time of the alert, the patient had excellent 20/20 acuity and was asymptomatic, exhibiting no visual changes on the Amsler Grid. The ForeseeHome detected the visual changes that allowed me to treat my patient before the lesion progressed, preserving his vision.

*Howard Fine, M.D.
Retina Vitreous Center
New Brunswick, NJ*