

Featured Patient Alert

US21026

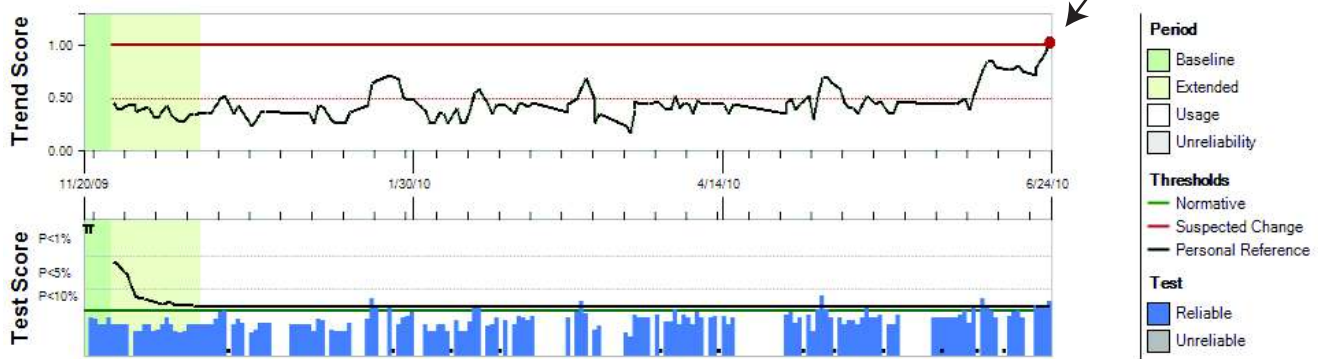
Patient History:

- 69 year old male
- OD AMD at baseline (Nov. 2009)
VA 20/40
Dry AMD

Testing:

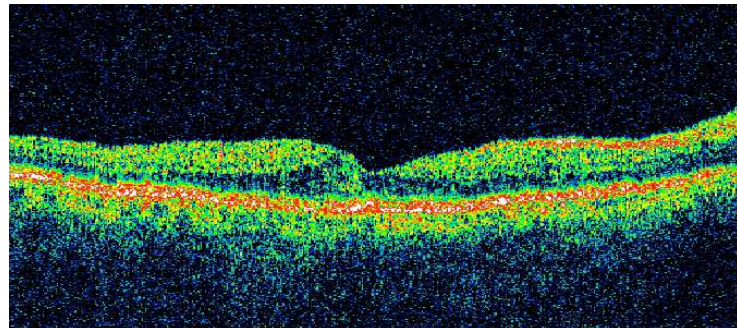
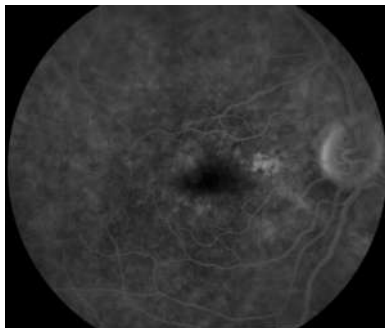
- ForeseeHome testing began Nov. 20, 2009
- Average frequency of use ≈ 7 times/week

June 24, 2010: ForeseeHome Alert



ALERT
VA 20/40
Patient experiencing no visual symptoms

July 6, 2010: FA and Stratus OCT



A Word From the Doctor



After my patient had been using the ForeseeHome AMD Monitor regularly for about 7 months we received an alert call from the Notal Vision Data Monitoring Center. He came in right away for an exam and OCT and FA imaging confirmed his conversion to wet AMD. At the time of the alert, the patient was asymptomatic and his visual acuity had not changed (20/40). The ForeseeHome allowed me to diagnose and treat my patient's wet AMD at it's earliest stage protecting his good vision.

*Daniel Roth, M.D.
Retina Vitreous Center
New Brunswick, NJ*